



**PATIENT**

Molly Ort

**SPECIES**

Canine

**BREED**

Yorkshire Terrier  
Cockapoo Mix

**SEX**

Female Spayed

**AGE**

16.4 years

**WEIGHT**

7.8lbs

**INTERPRETED BY**

Maggie Machen Lamy,  
DVM, DACVIM  
(Cardiology)

**IMAGING PERFORMED BY**

Christensen, DVM

**HOSPITAL NAME**

Tranquility Veterinary  
Clinic

**REFERRING VET**

Dr. Castellani

**INVOICE**

47125

**DATE**

3/5/26

**PRESENTING CLINICAL SIGNS**

History: Syncopal (O thought seizure at first) episode Sunday and Tuesday (yesterday) lasting 2 minutes with excitement. Currently on Vetmedin 1.25mg BID.

-Abnormal PE/Chem/CBC/UA Results (11/2025): anemia, increased monocytes, CKD, albumin low, ALT borderline increased.

**ECHOCARDIOGRAM FINDINGS**

2D, m-mode, color flow and doppler imaging is available. Diffuse thickening of mitral valve leaflets with prolapse into the left atrial lumen. Severe eccentric mitral regurgitation with severe left atrial enlargement. Normal MR velocity. Significant LV dilation with adequate myocardial function and evidence of volume overload. The tricuspid valve appears normal with mild tricuspid regurgitation. Mild right heart enlargement. The pulmonic and aortic valves appear normal in appearance and mobility. Normal pulmonic and aortic outflow velocities. No aortic or pulmonic insufficiency noted. No effusions or tumors.

**CARDIAC CHART**

CANINE CARDIAC PARAMETERS	MR VMAX (m/s)	TR VMAX (m/s)	LA/AO (Boon method)	LA/AO (Heart Base; Swe)	FS (%)	EF (%)	EPSS (cm)
<b>NORMAL PARAMETER</b>	4.5-5.5	<2.7	1.3	<1.6	28-40	40-100	<0.6
<b>PATIENT</b>	5.2	NM	2.3	2.2	54	86	0.2
CANINE CARDIAC PARAMETERS	HR (BPM)	AV VMAX (m/s)	PV MAX (m/s)	BODY WEIGHT (kg)	LA 2D short axis Base view (cm)	LVIDd Avg; 2D and m-mode short axis (cm)	LVIDs Avg; 2D and m-mode short axis (cm)
<b>NORMAL PARAMETER</b>	50-100	0.7-1.7	0.7-1.6	BELOW	BELOW	BELOW	BELOW
<b>PATIENT</b>	NM	0.9	0.8	18.1	2.7	3.0	1.4
*Normal chamber parameters expressed as a mean value (SD)				3	1.27 (5.3)	2.46 (2.46)	1.36 (5.5)
<b>BODY WEIGHT DEPENDENT PARAMETERS</b>				5	1.40 (4.5)	2.74 (5.2)	1.60 (4.7)
*Note: All measurements based upon multi-modal images and methods. An average value is reported.				10	1.50 (3.8)	3.27 (3.5)	2.06 (3.1)
				15	1.83 (2.0)	3.71 (2.4)	2.43 (2.1)
				20	2.02 (1.9)	4.14 (2.2)	2.80 (2.0)
				25	2.18 (2.4)	4.48 (2.9)	3.10 (2.5)
				30	2.33 (3.3)	4.83 (3.9)	3.39 (3.4)
				35	2.48 (4.3)	5.17 (5.0)	3.69 (4.5)
				40	2.62 (5.2)	5.48 (6.1)	3.96 (5.4)
				50	2.88 (7.1)	6.07 (8.3)	4.46 (7.4)

**INTERPRETATION OF THE FINDINGS & FURTHER RECOMMENDATIONS**

Chronic degenerative valve disease causing severe mitral and mild tricuspid regurgitation, certainly with evidence of progression. Severe left atrial and ventricular enlargement indicates there is an elevated risk for spontaneous congestive heart failure. No obvious pulmonary hypertension or significant right heart disease is seen, and no additional comorbidities such as systolic dysfunction are noted.



## PATIENT

Molly Ort

## SPECIES

Canine

## BREED

Yorkshire Terrier  
Cockapoo Mix

## SEX

Female Spayed

## AGE

16.4 years

## WEIGHT

7.8lbs

## INTERPRETED BY

Maggie Machen Lamy,  
DVM, DACVIM  
(Cardiology)

## IMAGING PERFORMED BY

Christensen, DVM

## HOSPITAL NAME

Tranquility Veterinary  
Clinic

## REFERRING VET

Dr. Castellani

## INVOICE

47125

## DATE

3/5/26

Syncope in this patient is concerning for a cardiogenic origin. Possible causes include poor forward blood flow leading to hypoxia, early CHF, significant pulmonary hypertension (not seen), an arrhythmia, vaso-vagal events, and/or blood pressure swings. In light of severity of disease on echocardiogram, early CHF is likely and **full lifelong cardiac supportive therapy is warranted** as below, including low-dose Lasix. Should syncope persist despite medications (particularly with exertion), revisiting the situational component of the episodes, arrhythmias, systemic possibilities, etc. is recommended.

Once in CHF, long term prognosis is guarded to poor, however most dogs are able to maintain a good QOL on medications for an average of 8-12 months. Patient will always be at risk for recurrent CHF, malignant arrhythmias, LA tear and/or sudden death in the future.

Monitoring of sleeping respiratory rates will be paramount to screen for congestive heart failure at home. Omega fatty acid supplementation and mild salt restriction may also be of some long-term benefit. Monitor for development of a cough, labored breathing, exercise intolerance or worsening collapse episodes in the future.

Elective anesthesia is not advised, as there is high risk for complication.

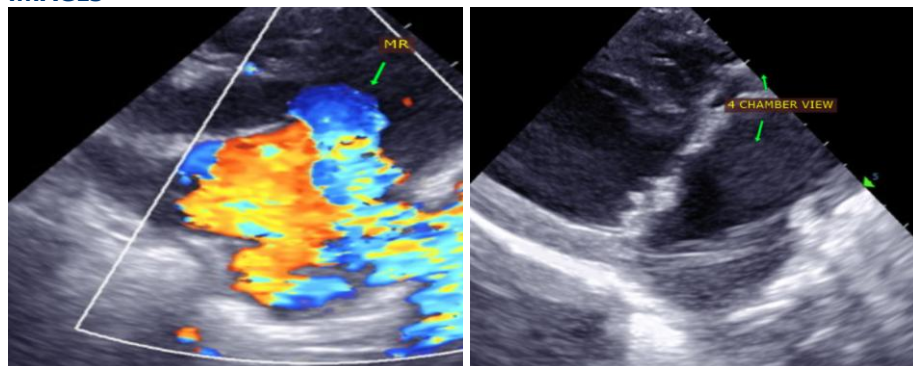
## PLAN

Baseline BP and CXR are recommended. Institute low dose Furosemide 1mg/kg PO q12h. Continue Pimobendan 0.2-0.3mg/kg PO q12h. Continue spironolactone 1-2mg/kg PO q12h. Institute ACE-I 0.5mg/kg PO q12h (pending BP >130mmHg).

Monitor renal values and BP in 10-14 days, then every 3-4 months while on diuretics.

Recommend conservative monitoring with a recheck echocardiogram in 6 months, sooner if any development of associated clinical signs occurs in the interim.

## IMAGES



The information and recommendations provided are based on the images presented by the referring veterinarian. No evaluation can be communicated regarding pathology that was not visible in the image/video clips provided.



## PATIENT

Molly Ort

## SPECIES

Canine

## BREED

Yorkshire Terrier  
Cockapoo Mix

## SEX

Female Spayed

## AGE

16.4 years

## WEIGHT

7.8lbs

## INTERPRETED BY

Maggie Machen Lamy,  
DVM, DACVIM  
(Cardiology)

## IMAGING PERFORMED BY

Christensen, DVM

## HOSPITAL NAME

Tranquility Veterinary  
Clinic

## REFERRING VET

Dr. Castellani

## INVOICE

47125

## DATE

3/5/26

Thank you for this referral. This report was generated using transcription software, and minor dictation errors may be present. If the clinical or image interpretation does not parallel your findings or if I can be of any further assistance, please contact me.

**Maggie Machen Lamy, DVM**  
**Diplomate of the American College of Veterinary Internal Medicine (Cardiology)**  
info@sonopath.com